




Antimicrobial Activity and Wound Healing Properties of *Aloe Arborescens* Extract: An *in Vivo* Study

Ghane Fatemeh¹ , Rasouli Pegah² , Khanjari Benafshe¹ , Yousofi Alireza³ , Zarenezhad Ali⁴ 
Fattahi Hossein⁵ , Rostami Chijan Mahsa^{4,6} , Ghasemian Abdolmajid⁴ , Miladpour Behnoosh⁷ 
Zarenezhad Elham⁴ 

1. Department of Chemistry, Darab branch, Islamic Azad University, Darab, Iran
2. Department of Chemistry, Fasa branch, Islamic Azad University, Fasa
3. Department of Pathology, Faculty of Veterinary Medicine, Kazerun Branch, Islamic Azad University, Kazerun, Iran
4. Noncommunicable Diseases Research Center, Fasa University of Medical Sciences, Fasa, Iran
5. Department of Microbiology, Faculty of Veterinary Medicine, Kazerun Branch, Islamic Azad University, Kazerun, Iran
6. Department of Persian Medicine, Fasa University of Medical Sciences, Fasa, Iran
7. Department of Clinical Biochemistry, Fasa University of Medical Sciences, Fasa, Iran

Article Info

Article Type:
Original Article

Article History:

Received
19 Feb 2023
Received in revised form
18 Apr 2023
Accepted
05 May 2023
Published online
15 May 2023

Publisher:
Fasa University of
Medical Sciences

Abstract

Background & Objective: Burn is one of the prominent causes of death around the world, however drug discovery attempts for burn healing has not been entirely successful. *Aloe arborescens* (*A. arborescens*), is effective in the burning wounds healing and growth inhibition of bacterial pathogens. Our objective was to assess the wound healing and antibacterial effects of *A. arborescens* in vivo.

Materials & Methods: Thirty healthy Wistar rat animals were enrolled. The treatment process continued for 21 days and sampling was conducted on days 14 and 21 and the tissue slides were sent to the pathology laboratory for testing. The bactericidal activity of *A. arborescens* extract was evaluated using the disc diffusion method.

Results: *A. arborescens* demonstrated a significant effect on the healing of burn wounds. Furthermore, the antibacterial effects of the *A. arborescens* extract against Gram-negative (*Escherichia coli*, *Pseudomonas aeruginosa*) was significantly higher than that against Gram-positive (*Staphylococcus aureus*, *Bacillus cereus*) bacterial species.

Conclusion: In conclusion, this study indicated that *A. arborescens* extract had an improving effect on the healing process of third degree burns without toxicity to the tissue.

Keywords: Wound healing; Burns, Herbal Medicines, *Aloe Arborescens*, *in vivo*

Cite this article: Ghane F, Rasouli P, Khanjari B, Yousofi A, Zarenezhad A, Fattahi H, Rostami Chijan M, Ghasemian A, Miladpour B, Zarenezhad E. Antimicrobial Activity and Wound Healing Properties of *Aloe Arborescens* Extract: An *in Vivo* Study. JABS.2023;13(2): 138-147.

DOI: 10.18502/jabs.v13i2.12726

Introduction

The skin is the largest tissue of the human body and performs various functions including

✉ Corresponding Authors:

1. Zarenezhad Elham, Noncommunicable Diseases Research Center, Fasa University of Medical Sciences, Fasa, Iran

Email: El.zarenezhad@gmail.com

2. Ghasemian Abdolmajid, Noncommunicable Diseases Research Center, Fasa University of Medical Sciences, Fasa, Iran

Email: majidghasemian86@gmail.com

preventing the penetration of pathogens into the body, protecting the underlying structure, preserving the body's water, etc (1). The human skin has a non-homogeneous three-layer tissue, with different thermal and physical properties (2). The epidermis is the outermost layer of skin which is in direct contact with the outside environment. This layer is constantly renewed and contains keratinocytes with various degrees of differentiation (3).

Burning is one of the most important problems in the world, particularly in developing countries. A serious side effect of burns is short-term or long-term disability (4). Despite the decline in the number of burns over the past decade, there are still more than one million burn injuries each year in the United States, resulting in more than 500,000 emergency department visits (5). Burns can develop into deep wounds due to damage to the skin and appendages, and due to heat transfer they can be one of the most severe forms of injury and can result in full-thickness burns (third-degree), damage to the epidermis and the entire dermis (6, 7). Although being self-relief, the intricate healing burn wound process is uncomfortable and perilous for patient due to the slow process and increased possibility to skin infections (8). Another important complication of burns is temporary or permanent deficits in organ function. Therefore, accelerating the wound healing process is of great importance in this regard (9). Physiopathological observations performed immediately after-burn indicate the existence of three distinct areas in the burn wound (10). The speed of wound healing in skin burns is crucial in terms of the costs incurred to the hospital, the health system, and the patient. The method that reduces recovery time will also reduce the financial and psychological influences.

Various drugs and agents have been applied for the topical treatment of burn wounds such as pamadastate mofenide, silver sulfadiazine, silver nitrate, and biological coatings (such as Biobran) (11). Standard methods today include daily dressing with Vaseline or antibiotics creams such as silver sulfadiazine cream mostly used to treat burn injuries (12).

Mafnid acetate is associated with pain or burning sensation at the site of consumption, and repeated use of silver nitrate due to restored silver also results in permanent discoloration of the skin. Also, using Silver sulfadiazine causes reduction in platelet and neutrophil counts (13). Herbal medicines are getting significant attention all over the world for treating various diseases (14), in particular against microbial

agents exhibiting antimicrobial resistance (15).

Aloe arborescens (*A. arborescens*) or *Candelabra Aloe* is a species of *Aloe* and belongs to *Asphodelaceae* (*Liliaceae*) family. It is cultivated as an ornamental plant. Generally, *Aloe* grows in Africa, Asia, Europe and America (16). *A. arborescens*, like *Aloe Vera*, is effective in treating burn wounds and in reducing the growth of germs and bacteria for the treatment of cancer according to a specific protocol. It is useful for treating a wide range of fungi and viruses, especially those invading the mucous membrane. It is also used to strengthen the immune system and regenerate cells (16). The Egyptian Book of Remedies (1500 BC) has talked about the use of *A. arborescens* for the treatment of infections, the treatment of skin, and the preparation of laxative medicines. *A. arborescens* possesses numerous biological activities such as anti-oxidant, antiviral, antitumor, anti-inflammatory and laxative traits (16). It also contains vitamins, enzymes, minerals, sugars, lignin, saponins, salicylic acids and amino acids (17).

Bacterial skin infections cause high morbidity and mortality, to address this health concern antimicrobial wound dressings to prevent wound contamination have been developed (18, 19). This anti-microbial agent contains essentially antibiotics, nanoparticles, natural products such as essential oils and honey (20-22).

In this research, the histopathologic effect of *A. arborescens* on third-degree burn and its anti-bacterial effect against *Bacillus cereus* (*B. cereus*), *Escherichia coli* (*E. coli*), *Staphylococcus aureus* (*S. aureus*) and *Pseudomonas aeruginosa* (*P. aeruginosa*) was investigated.

Materials and Methods

Preparation of *A. arborescens* extract

Mature leaves from *A. arborescens* were collected from northern Iran. The leaves were washed with water and ground and homogenized in a mixer. The product was obtained (502 g) and lyophilized with a freeze dryer at -20°C . This dry extract was weighed and soaked in water. Finally, the *A. arborescens* gel was used.

Determination of antibacterial activity of *A. arborescens* extract

The antibacterial activity of *A. arborescens* extract was evaluated using disc diffusion method (23-25). A stock solution of extract was prepared by dissolving 0.1 g of extract with 100 mL of distilled water (100 mg/mL) and then, diluted into 50 mg/mL concentration. In this study, *S. aureus* (ATCC: 25923), *S. cereus* (ATCC: 14579), as Gram-positive, and *E. coli* (ATCC: 25922) and *P. aeruginosa* (ATCC: 27853), as Gram-negative bacteria were used. 20 µL of each dilution (100 and 50 mg/mL) was impregnated into sterile, blank discs 6 mm in diameter. Antibacterial activity was investigated by measuring the diameter of the inhibition zone around the discs.

Determination of histopathologic effect of *A. arborescens* on third-degree burn

In this experimental study, the effect of *A. arborescens* extract on the healing process of third-degree burns in rats with the control group and incurable was performed (26). Thirty rats of the Wistar race with approximate weight 180 to 220 grams were tested without any skin and infectious diseases. They were randomly divided into three groups (Normal group,

Burn group without treatment, Burn group + Treatment with *A. arborescens*) with 10 rats in each. Third-degree burns, the entire thickness of the skin is destroyed, namely, the epidermis and dermis, and may even deepen the injury and involve subcutaneous tissues (fat, muscle, and bone). Sometimes, it is difficult to distinguish third-degree burns from second-degree burns. However, the burn area in the third degree is usually black or dry and white but the second-degree type is red and moist and has a sweaty appearance. After the rats were anesthetized with xylazine, their hair was shaved and third-degree burn was created by hot copper. The treatment process continued for 21 days and sampling was done on days 14 and 21 and the slides were sent to the pathology laboratory for testing.

Results

Antimicrobial Efficacy of *A. arborescens* extract

The *A. arborescens* extract displayed remarkable antimicrobial activity against Gram-positive including (*S. aureus*, *S. cereus*) and Gram-negative (*E. coli*, *P. aeruginosa*) bacteria, as shown in Table 1.

Table1. Antimicrobial activity of *A. arborescens* extract with disc diffusion method

Parameter	Gram-negative			
	<i>E. coli</i>	<i>P. aeruginosa</i>	<i>S. aureus</i>	<i>B. cereus</i>
Concentration	Diameter			
	Inhibition			
	Zone (mm)			
100 mg/mL	15±2	18±2	4±1	10±2
50 mg/mL	11±3	15±4	2±2	8±3

According to the results of the disc diffusion assay, this plant was effective for the prevention of Gram-negative such as *E. coli*, *P. aeruginosa*, bacteria rather than Gram-positive including *S. aureus*, *S. cereus*. The diameter of the inhibition zone was associated with the concentration of the extract.

Gentamicin as a reference drug at two various concentration (10, 5 mg/mL) was shown

in table 2. This drug exhibited stronger inhibition against both Gram-negative and Gram-positive at two concentrations. But, our green method was very simple and efficient at non-toxic level. Notably, the antibacterial effects of the *A. arborescens* extract against Gram-negative (*E. coli*, *P. aeruginosa*) was significantly higher than those of Gram-positive including *S. aureus*, *S. cereus*.

Table 2. Antimicrobial activity of gentamicin with disc diffusion method

Parameter	Gram-negative			
	<i>E. coli</i>	<i>P. aeruginosa</i>	<i>S.aureus</i>	<i>B. cereus</i>
Concentration	Diameter		Inhibition	Zone (mm)
10 mg/mL	25±3	20±2	15±2	10±2
5 mg/mL	18±2	16±3	10±2	8±3

Kaithwas et al reported that *A. arborescens* gel displayed 6 mm inhibition zone in the cases of *E. coli* and *P. aeruginosa*, in this research the initial concentrations of microorganisms are unknown, but in our study *A. arborescens* extract showed 25±3 mm and 20±2 mm in (10 mg/mL) concentration against *E. coli* and *P. aeruginosa* respectively (27). Recently, Kaja Kupnik et al, reported that antimicrobial efficiency of *A. arborescens* inhibition zone included 14±2, 35±3, 20±2 and 20±2 mm for *E. coli*, *P. aeruginosa*, *B. cereus* and *P. fluorescens* respectively. They confirmed high-level potential of *A. arborescens* for further use in food, medicine, pharmaceutical industries and cosmetics (28).

Histopathologic effect of *A. arborescens* on third-degree burn

Histological findings showed that a progressive improvement after treatment with *A. arborescens* extract in wound healing during 21 days. For evaluating the histopathologic effect of *A. arborescens* in three groups including (Normal group, Burn group, Burn group + Treatment with *A. arborescens*, the concentration of 100 mg/mL was applied. Normal group: There were no burns in the area and the tissue was normal Burn group (Day 14): The new epidermis has not yet covered the entire wound and the stratified tissue was not formed. Slightly fleshy bud tissue was formed and hyperemia and collagen fibers were seen irregularly with inflammatory cells (Figure 1).

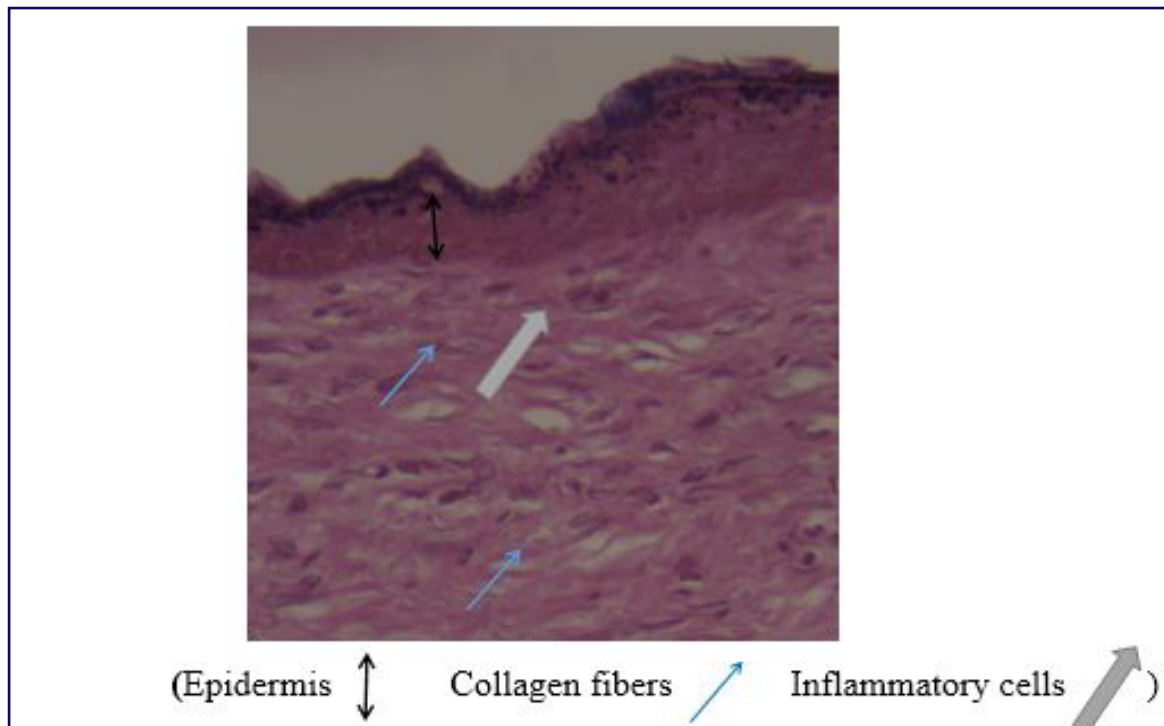


Figure 1. Microscopic view of burn (Day 14) (H&E, ×400)

Burn of Day 21: Epidermal tissue is completely stratified, fleshy bud tissue is seen, slightly inflammatory cells and hyperemia are seen (Figure 2).

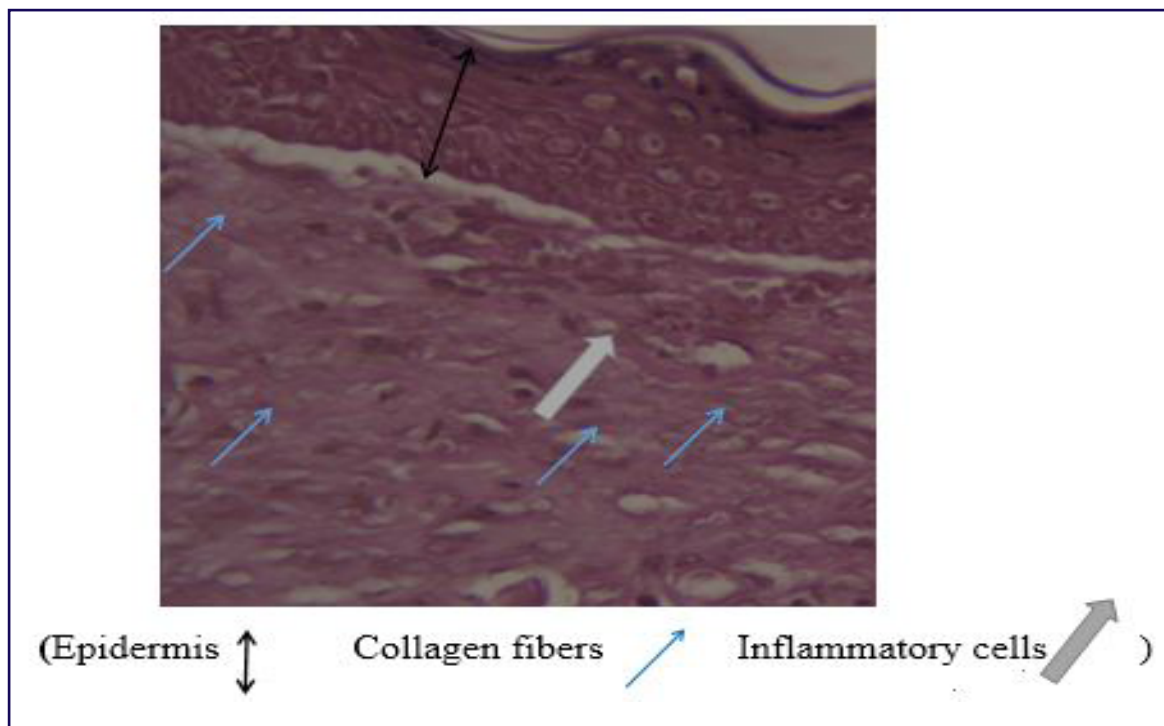


Figure 2. Microscopic view of burn (Day 21) (H&E, ×400)

A. arborescens extract ointment on Day 14: Epidermal growth and stratified are observed and appearance of fleshy

bud tissue and few inflammatory cells as well as blood vessels and subsequent angiogenesis (Figure 3).

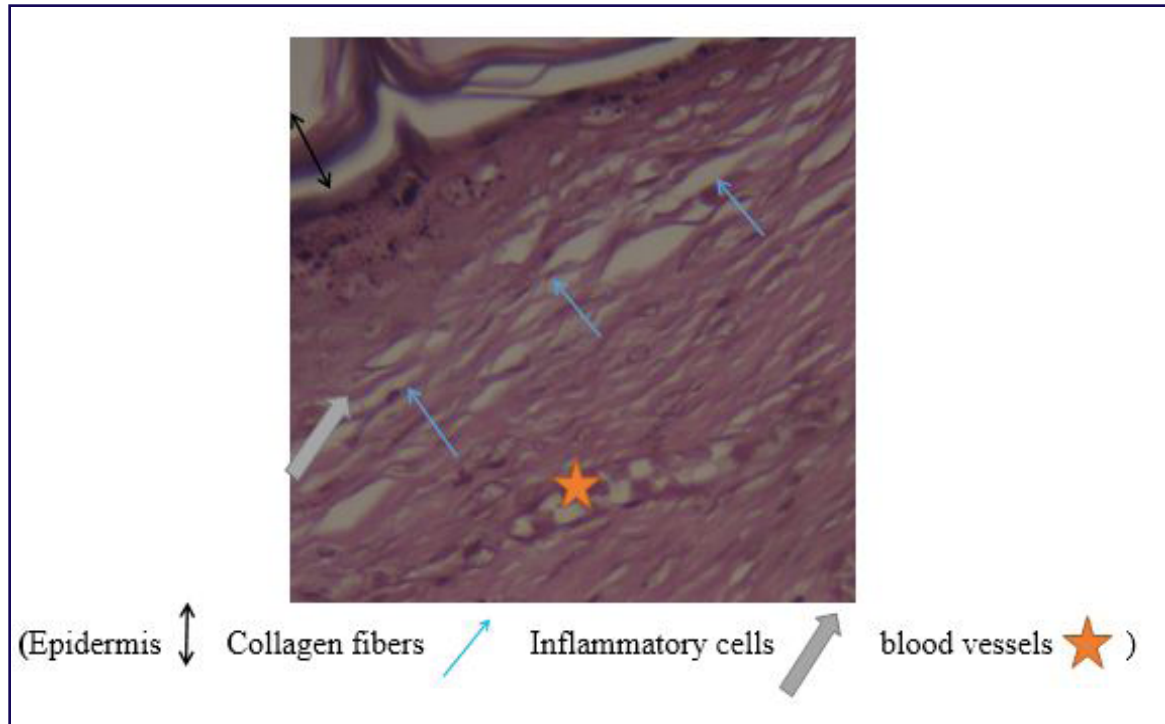


Figure 3. Microscopic view of burn group + treatment with *A. arborescens* extract ointment on day 14 (H&E, ×400)

Burn group + Treatment with *A. arborescens* extract Ointment on Day 21: Epidermal growth and stratified form are completely evident, and in this area,

the fleshy bud tissue covers the whole involved area, blood vessel inflammatory cells and fibrin are abundantly observed in this area (Figure 4).

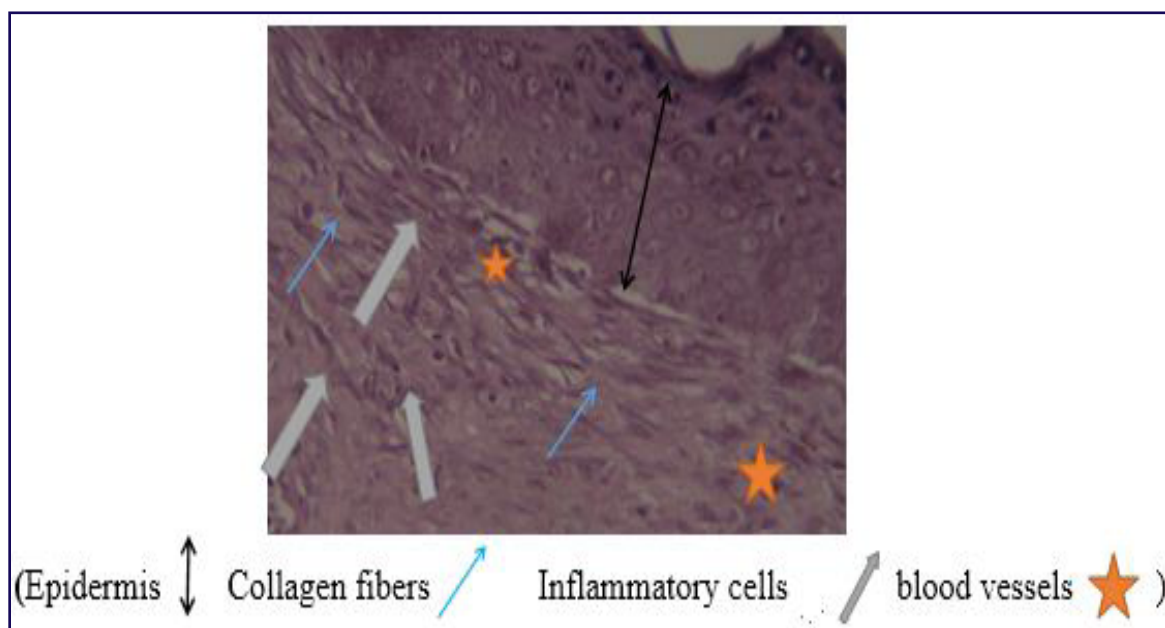


Figure 4. Microscopic view of burn group + treatment with *A. arborescens* extract ointment on day 21 (H&E, ×400)

Improvement of burn wounds using *A. arborescens* extract was shown in Figure 5.

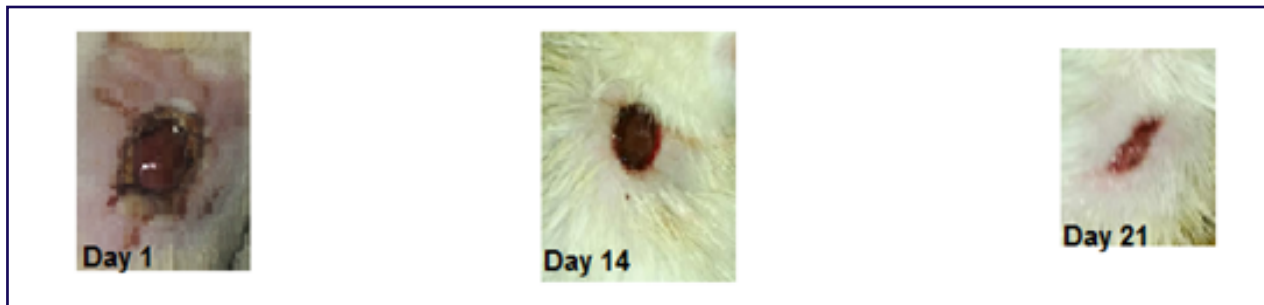


Figure 5. Progressive improvement of burn wound in rats treated with *A. Arborescens* extract

Discussion

The results of this study unraveled that the medicinal plant *A. arborescens* exerted promising healing effect on the third-degree burn. Angiogenesis and blood vessel development is one of the most effective factors in wound healing, thereby the plant led to the efficient wound healing process, preventing deepening of the wound (29-32).

Some researchers consider medicinal plants such as garlic extract as an antioxidant to prevent heat damage, banana leaf to prevent scarring in second-degree burns, honey to reduce inflammation and its antimicrobial activity in burn wounds (33-36). Henna and linseed herbs were suggested as a proper alternative for healing of wounds in second-degree burns (37). Some of these drugs accelerate the healing of burn wounds by boosting blood vessels, increasing the level of growth and proliferation of fibroblasts and creating a humid environment (38, 39). Silver Sulfadiazine is also a common drug for healing wounds, however it is believed that silver group drugs have toxic effects and have reported a negative effect on the growth, the number of fibroblasts, and collagen formation (40-43). The use of the medicinal plant in combination with some common drugs such as Silver Sulfadiazine 1%, Silonofloxacin (44) and Sodium Nitrate require further verifications (41). This study lasted 21 days. On the 14th

day of treatment with *A. arborescens* burn group, epidermal growth and adhesion were observed and little presence of broiler bud tissue and inflammatory cells as well as little blood vessels followed by angiogenesis. In a study, minimum inhibitory concentration (MIC) value of *A. arborescens* leaf extract ranged 0.07 to 1.13 mg/mL against *E. coli*. The extract mechanism of action included inhibition of bacterial respiratory chain dehydrogenase and effects on cell integrity and membrane permeability (45). In this study, we did not determine the MIC values of the *A. arborescens*.

On 21st and the last day of treatment, the stratified skin epidermis growth was conveniently visible, with fleshy bud tissue covering the entire affected area, and blood vessels' inflammatory cells and fibrin in the area were highly visible. In contrast to a work by Hossein Nikzad et al. (46), there was no significant effect on the healing process of second-degree burn wounds in a trial of herbal medicines containing rosemary leaves. Application of *A. arborescens* extract on third degree burn wounds significantly decreased burn surface area and increased blood vessel and fibrin in comparison with control group. Major limitations of our study included low number of samples and lack of valid phenotypic antimicrobial tests such as MIC determination and biofilm inhibition, and molecular techniques to determine

related cellular pathways of wound healing.

Conclusion

This study indicated that *A. arborescens* extract had a positive effect on healing process of third degree burns. Also, the antibacterial effects of the *A. arborescens* extract against Gram-negative species (*E. coli*, *P. aeruginosa*) was significantly higher than those of Gram-positive species (*S. aureus*, *B. cereus*). Further research with higher number of samples is needed to verify those cellular pathways participating in the wound healing process. In addition, research on other herbal medicines or bioactive compounds is also justifiably applicable in this regard.

Funding

No funding was used in this study.

Ethical Approval

This research has been ethically approved with the ID of IR.FUMS.REC.1399.103.

Acknowledgements

The authors would like to appreciate Noncommunicable Diseases Research Center, Fasa University of Medical Sciences and Mehr Hospital Veterinary, Fasa branch (Number 99093).

Conflict of interest

There is no conflict of interest.

References

1. Harvey ED. 5 The Touching Organ: Allegory, Anatomy, and the Renaissance Skin Envelope. *Sensible Flesh*: University of Pennsylvania Press; 2020. p. 81-102.
2. Menon GK. New insights into skin structure: scratching the surface. *Advanced drug delivery reviews*. 2002;54:S3-S17.
3. Madison KC. Barrier function of the skin: "la raison d'être" of the epidermis. *Journal of investigative dermatology*. 2003;121(2):231-41.
4. Pruitt Jr BA, McManus AT, Kim SH, Goodwin CW. Burn wound infections: current status. *World journal of surgery*. 1998;22(2):135-45.
5. Harvey A, Towner E, Peden M, Soori H, Bartolomeos K. Injury prevention and the attainment of child and adolescent health. *Bulletin of the World Health Organization*. 2009;87:390-4.
6. Rani M, Schwacha MG. Aging and the pathogenic response to burn. *Aging and disease*. 2012;3(2):171.
7. Walker NJ, King KC. Acute and chronic thermal burn evaluation and management. *StatPearls [Internet]*. 2020.
8. Rowan MP, Cancio LC, Elster EA, Burmeister DM, Rose LF, Natesan S, et al. Burn wound healing and treatment: review and advancements. *Critical care*. 2015;19(1):1-12.
9. Shpichka A, Butnaru D, Bezrukov EA, Sukhanov RB, Atala A, Burdakovskii V, et al. Skin tissue regeneration for burn injury. *Stem cell research & therapy*. 2019;10(1):1-16.
10. Nielson CB, Duethman NC, Howard JM, Moncure M, Wood JG. Burns: pathophysiology of systemic complications and current management. *Journal of Burn Care & Research*. 2017;38(1):e469-e81.
11. Atkin L, Bučko Z, Montero EC, Cutting K, Moffatt C, Probst A, et al. Implementing TIMERS: the race against hard-to-heal wounds. *Journal of wound care*. 2019;28(3a):S1-S50.
12. Dai T, Huang Y-Y, K Sharma S, T Hashmi J, B Kurup D, R Hamblin M. Topical antimicrobials for burn wound infections. *Recent patents on anti-infective drug discovery*. 2010;5(2):124-51.
13. Bandyopadhyay D, Baruah H, Gupta B, Sharma S. Silver nano particles prevent platelet adhesion on immobilized fibrinogen. *Indian Journal of Clinical Biochemistry*. 2012;27(2):164-70.
14. Tilburt JC, Kaptchuk TJ. Herbal medicine research and global health: an ethical analysis. *Bulletin of the World Health Organization*. 2008;86:594-9.
15. van Langeveld I, Gagnon RC, Conrad PF, Gamelli RL, Martin B, Choudhry MA, et al. Multiple-drug resistance in burn patients: a retrospective study on the impact of antibiotic resistance on survival and length of stay. *Journal of Burn Care & Research*. 2017;38(2):99-105.
16. Surjushe A, Vasani R, Saple D. Aloe vera: a short review. *Indian journal of dermatology*. 2008;53(4):163.
17. Shelton RM. Aloe vera. *Int J Dermatol*. 1991;30(10):679-83.
18. Woodford N, Livermore DM. Infections caused by Gram-positive bacteria: a review of the global challenge. *Journal of Infection*. 2009;59:S4-S16.
19. Sonamuthu J, Cai Y, Liu H, Kasim MSM, Vasanthakumar VR, Pandi B, et al. MMP-9 responsive dipeptide-tempted natural protein

- hydrogel-based wound dressings for accelerated healing action of infected diabetic wound. *International journal of biological macromolecules*. 2020;153:1058-69.
20. Sarheed O, Ahmed A, Shouqair D, Boateng J. Antimicrobial dressings for improving wound healing. *Wound Healing-New Insights into Ancient Challenges*; Alexandrescu, V, Ed. 2016:373-98.
 21. Mouro C, Dunne CP, Gouveia IC. Designing New Antibacterial Wound Dressings: Development of a Dual Layer Cotton Material Coated with Poly (Vinyl Alcohol) _Chitosan Nanofibers Incorporating Agrimonia eupatoria L. Extract. *Molecules*. 2021;26(1):83.
 22. Homaeigohar S, Boccaccini AR. Antibacterial biohybrid nanofibers for wound dressings. *Acta biomaterialia*. 2020;107:25-49.
 23. Trinh P-C, Thao L-T-T, Ha H-T-V, Nguyen T. DPPH-scavenging and antimicrobial activities of asteraceae medicinal plants on uropathogenic bacteria. *Evidence-Based Complementary and Alternative Medicine*. 2020;2020.
 24. Zarenezhad E, Mosslemine MH, Alborzi A, Anaraki-Ardakani H, Shams N, Khoshnood MM, et al. Efficient synthesis of 3, 4-dihydro-1 H-quinoxalin-2-ones and 1 H-quinolin-2-ones and evaluation of their anti-bacterial activity. *Journal of Chemical Research*. 2014;38(6):337-40.
 25. Behrouz S, Rad MNS, Rostami S, Behrouz M, Zarenezhad E, Zarenezhad A. Design, synthesis, and biological activities of novel azole-bonded β -hydroxypropyl oxime O-ethers. *Molecular diversity*. 2014;18(4):797-808.
 26. Vaghardoost R, Ghavami Y, Sobouti B. The effect of Mentha pulegium on healing of burn wound injuries in rat. *World journal of plastic surgery*. 2019;8(1):43.
 27. Kaithwas G, Kumar A, Pandey H, Acharya AK, Singh M, Bhatia D, et al. Investigation of comparative antimicrobial activity of Aloe vera gel and juice. *Pharmacologyonline*. 2008;1:239-43.
 28. Kupnik K, Primožič M, Knez Ž, Leitgeb M. Antimicrobial Efficiency of Aloe arborescens and Aloe barbadensis Natural and Commercial Products. *Plants*. 2021;10(1):92.
 29. Okonkwo UA, Chen L, Ma D, Haywood VA, Barakat M, Urao N, et al. Compromised angiogenesis and vascular Integrity in impaired diabetic wound healing. *PloS one*. 2020;15(4):e0231962.
 30. Zehra M, Zubairi W, Hasan A, Butt H, Ramzan A, Azam M, et al. Oxygen generating polymeric nano fibers that stimulate angiogenesis and show efficient wound healing in a diabetic wound model. *International journal of nanomedicine*. 2020;15:3511.
 31. Hao Y, Zhao W, Zhang L, Zeng X, Sun Z, Zhang D, et al. Bio-multifunctional alginate/chitosan/fucoidan sponges with enhanced angiogenesis and hair follicle regeneration for promoting full-thickness wound healing. *Materials & Design*. 2020;193:108863.
 32. Guo H-f, Abd Hamid R, Mohd Ali R, Chang SK, Rahman MH, Zainal Z, et al. Healing properties of epidermal growth factor and tocotrienol-rich fraction in deep partial-thickness experimental burn wounds. *Antioxidants*. 2020;9(2):130.
 33. PIGGIES CBWI. Comparison of efficacy of honey versus silver sulfadiazine and acetate mafenid in the treatment of contaminated burn wounds in piggies. *Pak J Med Sci April-June*. 2005;21(2):168-73.
 34. Molan PC. Potential of honey in the treatment of wounds and burns. *American journal of clinical dermatology*. 2001;2(1):13-9.
 35. Ndayisaba G, Bazira L, Habonimana E. Treatment of wounds with honey. 40 cases. *Presse medicale (Paris, France)*. 1983. 1992;21(32):1516-8.
 36. Jalilian F, Chahardoli A, Sadrjavadi K, Fattahi A, Shokoohinia Y. Green synthesized silver nanoparticle from Allium ampeloprasum aqueous extract: Characterization, antioxidant activities, antibacterial and cytotoxicity effects. *Advanced Powder Technology*. 2020;31(3):1323-32.
 37. Naseri S, Golpich M, Roshancheshm T, Joobeni MG, Khodayari M, Noori S, et al. The effect of henna and linseed herbal ointment blend on wound healing in rats with second-degree burns. *Burns*. 2020.
 38. Salakhiddinov KZ, Alekseev AA, Kilichev MR, Niyazova ZA. Current aspects in the treatment of burn wounds. *Вопросы науки и образования*. 2020(13):93-7.
 39. Komi DEA, Khomtchouk K, Santa Maria PL. A review of the contribution of mast cells in wound healing: involved molecular and cellular mechanisms. *Clinical reviews in allergy & immunology*. 2020;58(3):298-312.
 40. Fraser JF, Cuttle L, Kempf M, Kimble RM. Cytotoxicity of topical antimicrobial agents used in burn wounds in Australasia. *ANZ journal of surgery*. 2004;74(3):139-42.
 41. Lee A-RC, Moon HK. Effect of topically applied silver sulfadiazine on fibroblast cell proliferation and biomechanical properties of the wound. *Archives of pharmacal research*. 2003;26(10):855-60.
 42. Di Domenico EG, De Angelis B, Cavallo I, Sivori F, Orlandi F, Fernandes Lopes Morais D'Autilio M, et al. Silver Sulfadiazine Eradicates Antibiotic-Tolerant Staphylococcus aureus and

- Pseudomonas aeruginosa* Biofilms in Patients with Infected Diabetic Foot Ulcers. *Journal of Clinical Medicine*. 2020;9(12):3807.
43. Lima Júnior EM, Moraes Filho MOd, Forte AJ, Costa BA, Fachine FV, Alves APNN, et al. Pediatric burn treatment using tilapia skin as a xenograft for superficial partial-thickness wounds: a pilot study. *Journal of Burn Care & Research*. 2020;41(2):241-7.
44. Giamarellos-Bourboulis E, Grecka P, Dionyssiou-Asteriou A, Giamarellou H. In vitro interactions of [gamma]-Linolenic acid and arachidonic acid with ceftazidime on multiresistant *Pseudomonas aeruginosa*. *Lipids*. 1999;34:S151.
45. Maliehe TS, Nqotheni MI, Shandu JS, Selepe TN, Masoko P, Poole OJ. Chemical Profile, Antioxidant and Antibacterial Activities, Mechanisms of Action of the Leaf Extract of *Aloe arborescens* Mill. *Plants (Basel)*. 2023;12(4).
46. Nikzad H, Atlasi MA, Naseri Esfahani AH, Naderian H, Nikzad M. Effect of *Arnebia* leaf on the healing process of rat's second degree burn. *KAUMS Journal (FEYZ)*. 2010;14 (2):99-106.