



Original Article

## Comparative Effect of Bromelain and Vitamin E on Bisphenol A-induced Skeletal Anomalies in the Rat Fetus

Khazaeel K<sup>1,2\*</sup>, Khaksary-Mahabady M<sup>1,3</sup>, Jamshidian J<sup>1</sup>, Zolfaghari N<sup>1</sup>

1. Department of Basic Sciences, Faculty of Veterinary Medicine, Shahid Chamran University of Ahvaz, Ahvaz, Iran

2. Stem Cells and Transgenic Technology Research Center (STTRC), Shahid Chamran University of Ahvaz, Ahvaz, Iran

3. Anatomical science Research Center, Kashan University of Medical Sciences, Kashan, Iran

Received: 09 Feb 2021

Accepted: 20 Apr 2021

### Abstract

**Background & Objective:** The teratogenic and embryotoxic potential of Bisphenol A (BPA) has been identified in recent years. Bromelain is a natural compound of pineapple that contains different beneficial effects on the fetus. So, this study aimed to investigate the effect of bromelain against BPA-induced skeletal anomalies in the rat fetuses.

**Materials & Methods:** In this experimental study, 36 pregnant Wistar rats were divided into 6 groups including control, BPA (300 mg/kg), Bromelain (40 mg/kg), BPA + Bromelain (10 mg/kg), BPA + Bromelain (40 mg/kg) and BPA + Vitamin E (100 mg/kg). The treatment period was at the 6-15th days of gestation. Fetuses were collected at the 20th day of gestation and after clarification, the skeletal system was stained by Alizarin red and Alcian blue method. Then, skeletal anomalies were evaluated using a stereomicroscope.

**Results:** The BPA increased anomalies percentage of cleft palate, spina bifida, non-ossification of the sternum, non-ossification of the last rib, delayed ossification of the forelimb, non-ossification of forepaw, delayed ossification of hindlimb, and non-ossification of the hind paw. Administration of bromelain, as same as vitamin E, reduced the percentage of these anomalies. However, the higher dose of bromelain had a better effect than its lower dose and vitamin E.

**Conclusion:** Bromelain is dose-dependent and even better than vitamin E, can reduce skeletal anomalies induced by bisphenol A in the rat fetus.

**Keywords:** Bisphenol A, Bromelain, Skeletal Anomalies, Fetus

### Introduction

The use of plastic materials nowadays has caused concern due to its effect on the functioning of the endocrine system. Bisphenol A (BPA) is a compound that is used in plastic manufacturing, disposable containers, food packaging, baby bottles,

laboratory instruments, electronics, plastic tubes, and toys (1). According to previous studies, BPA molecules in polycarbonate plastics can enter to diet and the human body when heated or exposed to acids and alkalis (2). This substance passes the blood-placental barrier due to its fat solubility. Also, BPA has poor estrogenic activity and leads to increased testicular and breast cancer, decreased fertility, , developmental anomalies, changes in endocrine function,

\*Corresponding Author: Department of Basic Sciences, Faculty of Veterinary Medicine, Stem Cells and Transgenic Technology Research Center (STTRC), Shahid Chamran University of Ahvaz, Ahvaz, Iran  
Email: k.khazaeil@scu.ac.ir  
Tel: +989166033806  
<https://orcid.org/0000-0002-4505-1106>



decreased immune function, and adverse effects on the fetus (3). Previous studies have reported that oral administration of BPA at doses of 300 and 600 mg/kg in pregnant rats significantly reduced fetal length (3, 4). Moreover, other studies have shown that high doses of BPA impair fetal lung development and fetal development (5, 6). In studies on the rat's liver, it was reported that BPA increased reactive oxygen species (ROS) production and oxidative stress by reducing the liver antioxidant enzyme activity (7) and increasing malondialdehyde (MDA) levels and decreasing glutathione (GSH) levels in the brain (8). Other detrimental effects of BPA on rat embryos are apoptosis induction and inhibition of cell proliferation (9). In the animal models, many studies have reported that receiving BPA in the prenatal period can induce congenital defects, such as testicular histopathological alterations (10), craniofacial malformations (11) and underdevelopment of the brain (12).

Bromelain is a natural compound of pineapple (*Ananas comosus* L.) that contains different agents such as thiol endopeptidase, and proteinase inhibitors such as cysteine, phosphatase, peroxidase, cellulose, glycoprotein, and carbohydrates (13, 14). Its main pharmaceutical properties are associated with proteolytic effects that improve the function of the gastrointestinal tract and facilitate muscle and joints activity (15). It has been shown that bromelain has anti-inflammatory, anti-edematous, anti-coagulation, and anti-platelet aggregation properties, anti-atherosclerosis, anti-angiogenic, anti-osteoarthritis, anti-cancer, anti-parasitic, and anti-bacterial (16). Moreover, the beneficial effects of bromelain in reducing pain and healing wounds and burns have been mentioned. The Food and Drug Administration classifies bromelain as an authorized dietary supplement and certifies its health (14). Injections of 30-35 mg/kg bromelain have been reported to cause death in mice; however, oral administration of up to 10 g/kg in mice, rats, and rabbits has not shown any mortality (16). In some experimental models, it has been shown that bromelain can significantly increase the activity of antioxidant enzymes and inhibits oxidative stress (17). Also, it has been reported that bromelain increases the function of the immune system (15).

Studies on vitamin E have also shown its anti-inflammatory and antioxidant properties to improve embryo development (18). The roles of vitamin E during the periconceptional period have been reported (19, 20). This Vitamin play important roles within the placenta as well as in the protection of trophoblast cells from oxidative stress (20). Also, vitamin E to be efficient in reproductive- and pregnancy-related disorders (21).

Therefore, this study aimed to compare the protective effect of bromelain and vitamin E against BPA-induced skeletal anomalies in rat fetuses.

## **Materials and Methods**

### **Animals**

In this experimental study, mature male and female Wistar rats (4 months of age, 200-220 g body weight) were purchased from Laboratory Animal Center, Jundishapur University, Ahvaz, Iran. The female and male animals separately were placed in clean polycarbonate cages under standard conditions of temperature ( $22 \pm 2^{\circ}\text{C}$ ), relative humidity ( $50 \pm 10\%$ ), and light (12 hours light/12 hour dark). Animals were fed standard pellets (Pars Khurakdam, Tehran, Iran) and had free access to fresh drinking water. Animal work was performed according to the Guidelines for the Humane Care and Use of Laboratory Animals using protocols approved by the Shahid Chamran University of Ahvaz.

### **Experimental design**

Female rats were mated overnight with males. Pregnancy was ascertained the next morning by the presence of a vaginal plug, and this time was designated as a gestational day (GD) 0. Thirty-six pregnant rats were divided into six groups (n=6) including control, BPA (300 mg/kg), Bromelain (40 mg/kg), BPA (300 mg/kg) + Bromelain (10 mg/kg), BPA (300 mg/kg) + Bromelain (40 mg/kg) and BPA (300 mg/kg) + Vitamin E (100 mg/kg). The administration of BPA (Merck, Germany) was oral, and the administration of bromelain (Acros Organic, Thailand) and vitamin E (Osveh, Iran) was intraperitoneally (22, 23). BPA and bromelain dissolved in



olive oil (Mazo Light, Tehran, Iran) and distilled water, respectively.

To determine the bromelain doses, a pilot study was conducted in which 15 male rats received bromelain for 10 weeks with 10, 40, and 70 mg/kg doses for intraperitoneal administration in three groups of 5. In the end, the doses of 10 and 40 mg/kg were considered as therapeutic doses and the highest value specified in the pilot study, respectively. Moreover, the dose of 70 mg/kg was not selected due to undesirable reactions.

### Sampling

On the 20th day of gestation, the treated pregnant rats were euthanized with ketamine (Alfasan, Woerden, Netherlands; 75.00 mg/kg, IP) and xylazine (Alfasan, Woerden, Netherlands; 10.00 mg/kg, IP). After opening the abdominal cavity and cutting the horn of the uterus, the fetuses were taken out from the uterus of the rats and immediately removed from the amniotic sac. Then, the skin and viscera were removed, and the fetuses were fixed in 96-degree alcohol for anomalies investigation.

### Anomalies Analyses

For anomalies analysis, the fetuses were placed in a mixture of 14.5% Alcian blue and 12.5% Alizarin red in ethanol and glacial acetic acid. After being placed in the potassium solution with glycerin and distilled water, they were eventually placed in the pure glycerin solution. The anomalies of Cleft palate, Non-ossification of the sternum, Spina bifida, Non-ossification of the last rib, Delayed ossification of the forelimb, Non-ossification of forepaw, Delayed ossification of hind limb and Non-ossification of the hind paw were evaluated using a stereomicroscope (Nikon, SMZ 800, Japan).

### Statistical analysis

The results were analyzed by SPSS software (Version 16, SPSS Inc, Chicago, IL). Groups were compared using one-way ANOVA and Tukey's post hoc test. The significance level was  $P \leq 0.05$ .

### Results

The results of a stereomicroscopic assessment of fetal skeletal anomalies in different groups are shown in Table 1. According to this table, administration of BPA caused the cleft palate abnormality in rat fetuses ( $p < 0.05$ ; Figure 1). Although this abnormality significantly decreased by receiving 10 mg/kg bromelain and vitamin E compared to the BPA group, this reduction was statistically significant to the control group ( $p < 0.05$ ), while receiving BPA with 40 mg/kg bromelain was not significantly different compared to the control ( $p > 0.05$ ).

The fetuses of the BPA group showed spina bifida anomaly (Figure 1) in 36.74% of cases. Although the administration of bromelain with a dose of 10 mg/kg declined this anomaly, the mean difference was statistically significant compared to the control ( $p < 0.05$ ), while by receiving bromelain with a dose of 40 mg/kg, the incidence of the anomaly was reduced to zero ( $p > 0.05$ ). Vitamin E also significantly decreased this abnormality (compared with the BPA group) but did not reduce it to zero. However, the mean difference between the groups that received vitamin E plus bromelain was not statistically significant ( $p > 0.05$ ).

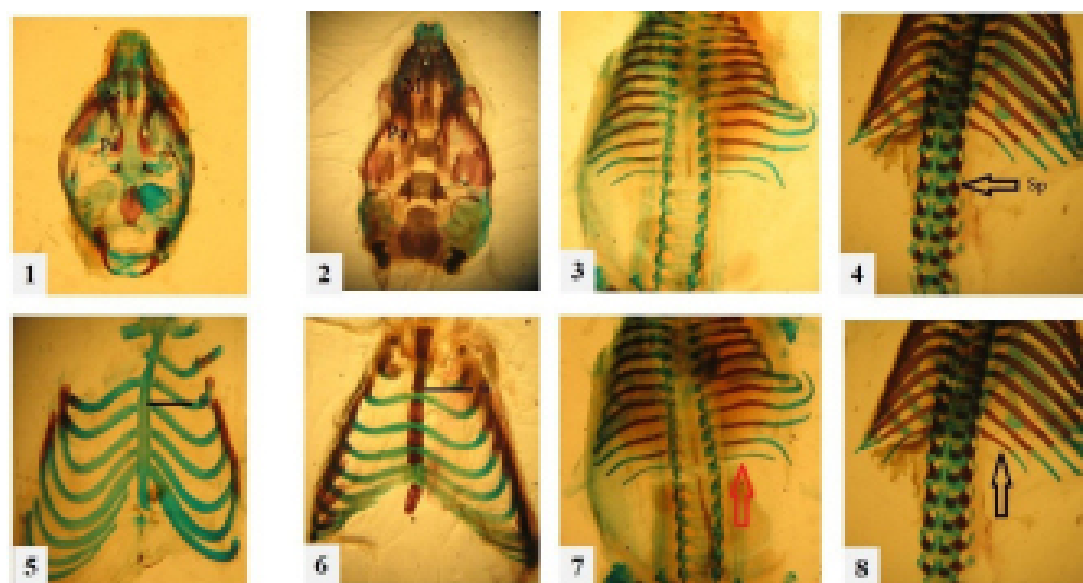
Receiving BPA in 48.41% of fetuses was associated with non-ossification of the sternum (Figure 1). Receiving vitamin E plus BPA decreased this abnormality, the mean difference was not significant compared to control ( $p < 0.05$ ). Although bromelain with a dose of 10 mg/kg caused a significant decline in this abnormality compared with the BPA group ( $p < 0.05$ ), but the best effect was related to bromelains with a dose of 40 mg/kg which reduced the incidence of this abnormality to zero ( $p > 0.05$ ).

The fetuses of the BPA group showed non-ossification of the last rib (Figure 1) which was statistically significant compared with other groups ( $p < 0.05$ ). The other groups were not significantly different from the control group ( $p > 0.05$ ). The anomaly of delayed ossification of forelimb was observed in the the fetuses of the BPA group ( $p < 0.05$ ; Figure 2).

**Table 1.** The percentage of fetal skeletal anomalies in different groups.

Groups	Cleft palate (%)	Spina bifida (%)	Non-ossification of the sternum (%)	Non-ossification of the last rib (%)	Delayed ossification of the forelimb (%)	Non-ossification of forepaw (%)	Delayed ossification of the hind limb (%)	Non-ossification of the hind paw (%)
Control	0.00±00 <sup>a</sup>	0.00±00 <sup>a</sup>	0.00±00 <sup>a</sup>	0.00±00 <sup>a</sup>	0.00±00 <sup>a</sup>	0.00±00 <sup>a</sup>	0.00±00 <sup>a</sup>	0.00±00 <sup>a</sup>
BPA	59.95±6.36 <sup>b</sup>	36.74±4.91 <sup>b</sup>	48.41±4.13 <sup>b</sup>	9.88±4.63 <sup>b</sup>	40.91±4.68 <sup>b</sup>	41.86±5.02 <sup>b</sup>	40.91±4.68 <sup>b</sup>	40.91±4.68 <sup>b</sup>
Bromelain (40 mg/kg)	0.00±00 <sup>a</sup>	0.00±00 <sup>a</sup>	0.00±00 <sup>a</sup>	0.00±00 <sup>a</sup>	0.00±00 <sup>a</sup>	0.00±00 <sup>a</sup>	0.00±00 <sup>a</sup>	0.00±00 <sup>a</sup>
BPA+ Bromelain (10 mg/kg)	29.12±3.92 <sup>c</sup>	16.42±0.85 <sup>c</sup>	15.51±3.75 <sup>c</sup>	0.00±00 <sup>a</sup>	9.91±4.85 <sup>a</sup>	10.31±3.29 <sup>a</sup>	10.87±3.54 <sup>a</sup>	10.87±3.54 <sup>a</sup>
BPA+ Bromelain (40 mg/kg)	0.00±00 <sup>a</sup>	0.00±00 <sup>a</sup>	0.00±00 <sup>a</sup>	0.00±00 <sup>a</sup>	3.93±2.49 <sup>a</sup>	3.93±2.49 <sup>a</sup>	3.93±2.49 <sup>a</sup>	3.93±2.49 <sup>a</sup>
BPA+ Vitamin E	26.66±3.52 <sup>c</sup>	5.55±3.51 <sup>a</sup>	6.11±3.88 <sup>ac</sup>	0.00±00 <sup>a</sup>	4.44±3.29 <sup>a</sup>	6.11±3.88 <sup>a</sup>	23.33±2.39 <sup>c</sup>	23.33±2.39 <sup>c</sup>

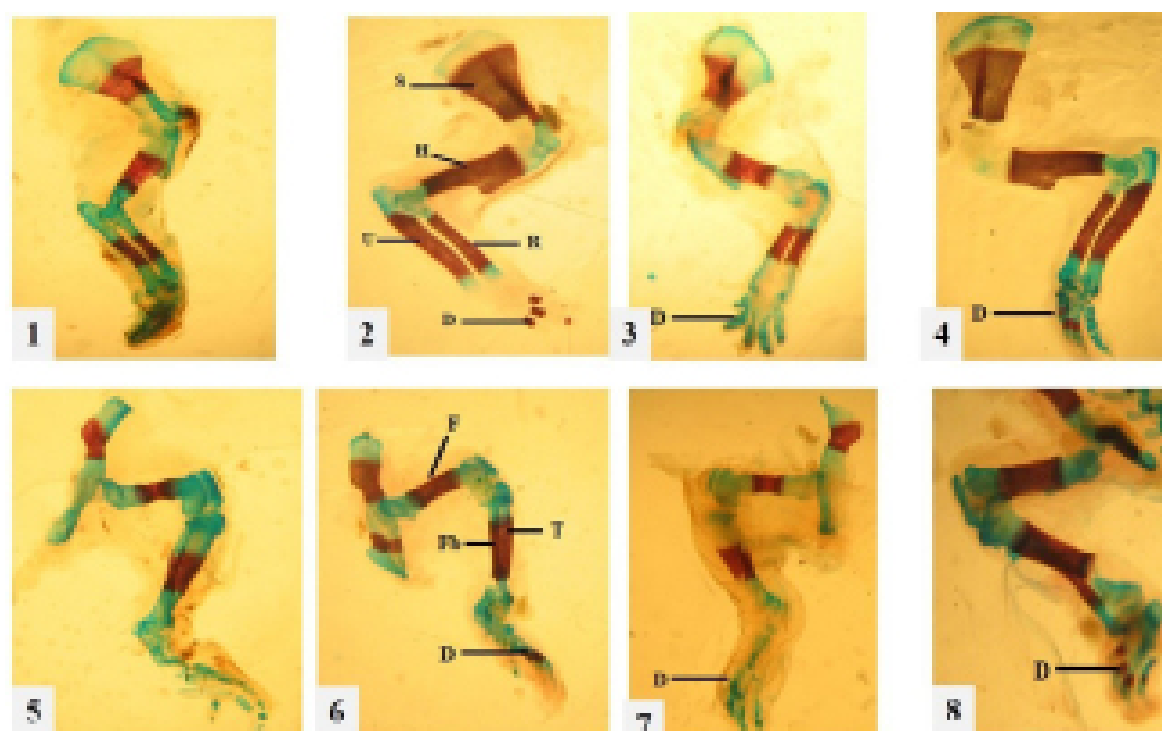
The different lower letters (a,b,c) in each column indicates a significant difference ( $p \leq 0.05$ ) between groups.


**Figure 1.** The axial skeleton of rat fetuses stained with Alizarin red - Alcian blue in 20th gestational day.

Ventral surface of the skull of rat fetuses after removing the mandible in the BPA+ Bromelain 10 mg/kg group with the cleft palate (1), and healthy rat fetus in the Bromelain group (2); Dorsal view of the vertebral column with Spina Bifida (red arrow) in the BPA group (3), and Healthy rat fetus in the control group (4); Ventral view of the sternum with non-ossification of the

sternum in the BPA group (5), and in the healthy fetus of the BPA+ Bromelain 40 mg/kg group (6), Dorsal view of spinal column and ribs which show the last rib being completely cartilaginous (red arrow) in the BPA group (7), and the healthy rib (black arrow) in the control group (8).

Pa: palatine, M: maxilla, SP: Spinal process, St: sternum



**Figure 2.** The appendicular skeleton of rat fetuses stained with Alizarin red - Alcian blue in 20th gestational day.

Lateral view of the right forelimb of rat fetuses which show delayed ossification in the BPA group (1), and healthy fetal rat in the control group (2); Lateral view of the left forelimb of rat fetuses with non-ossification of the forepaw in the BPA group (3), and healthy rat fetuses in the Bromelain group (4); Lateral view of the right hindlimb of rat fetuses with delayed ossification

in the BPA group (5), and healthy rat fetus in the Bromelain group (6); Lateral view of the left hindlimb with special attention to hind paw of rat fetuses which show non-ossification of the hind paw in the BPA+ Vitamin E group (7), and healthy rat fetus in the control group (8).

S: Scapula, H: Humerus, R: Radius, U: Ulna, D: Distal phalanges, F: Femur, T: Tibia, Fb: Fibula.



However, receiving bromelain and vitamin E plus BPA caused a significant decrease in the above-mentioned abnormality ( $p < 0.05$ ). Although this anomaly decreased more in group BPA with 40 mg/kg bromelain than in the vitamin E group, this difference was not statistically significant ( $p > 0.05$ ).

The administration of BPA in 41/91% of fetuses led to the non-ossification of forepaw ( $p < 0.05$ ; Figure 2). While receiving bromelain and vitamin E plus BPA was not significantly different compared to control ( $p > 0.05$ ). Although the effect of bromelain with a dose of 40 mg/kg on the reduction of this anomaly was much more than that of bromelain with a dose of 10 mg/kg and vitamin E, the mean difference between these groups was not statistically significant ( $p > 0.05$ ).

The administration of BPA showed a significant increase in delayed ossification of the hind limb (Figure 2), and non-ossification of the hind paw anomalies ( $p < 0.05$ ; Figure 2). Receiving vitamin E plus BPA decreased the incidence of these anomalies, however, the mean of these anomalies' percentage was significantly different compared to the control ( $p < 0.05$ ). On the other hand, receiving bromelain plus BPA caused a significant decrease in the incidence of these anomalies compared to the BPA group ( $p < 0.05$ ).

## Discussion

Bisphenol A (BPA) is a key monomer widely used in the manufacture of polycarbonate plastics and epoxy resins. Recently, it has been accepted that receiving BPA in the prenatal period can induce congenital defects (12). Bromelain is a natural compound of pineapple that increases the activity of antioxidant enzymes and inhibits oxidative stress (17). In the present study, it was found that the administration of BPA with a dose of 300 mg/kg in pregnant rats caused skeletal anomalies in fetuses and different proportions including cleft palate, split vertebra (Spina Bifida), and non-ossification of the sternum, last rib, forelimb, hind limb, forepaw, and hind paw. The most common anomaly was the cleft palate

and the least frequent anomaly was related to non-ossification of the last rib.

Bisphenol A has estrogenic activity and causes changes in the endocrine function, decreases the immune system's efficiency, affects the fetus, and increases the developmental malformations (24). Previously reported increased skeletal anomalies in fetuses whose mothers received BPA with a dose of 300 mg/kg; that most anomalies were observed in the skull bones, forepaw, hind paw, and thoracic vertebrae (4). Sharf-El Deen et al. (2015) investigated the teratogenicity of BPA in rats and reported the induced reduction in ossification of the skull concerning the dosage and time of administration. They also observed malformations in ribs, vertebral column, and forelimb/hind limb, but the parts mostly involved were reported as skull bones (3) these reports are in agreement with the results of the present study as the most common anomalies in this study were related to the cleft palate. Kim et al. (2001) pointed to the reduction of ossification centers in fetuses exposed to BPA and reported delayed ossification (25) which is consistent with the results of this study.

Considering that most of the skull and facial bones are made by mesenchymal cells derived from the neural crest (26), it does not seem unlikely that various phenol metabolites like BPA affect the process of differentiation of these cells, prevent them from converting into osteoblasts, and ultimately lead to skeletal anomalies including malformation of skull bones. Regarding anomalies in forelimb/hind limb, and given that limb buds in rats appear on the 9th and 10th embryonic days, it can be expected that the administration of BPA during the 6th and 15th gestation days also involves that sensitive period and causes developmental anomalies in the forelimb/hind limb. Moreover, Li et al. (2010) reported induced cell death, inhibited cell proliferation, and differentiation in fetuses exposed to BPA (27). They also mentioned the abnormal function of inducible Nitric Oxide Synthase (iNos) in embryonic cells due to BPA. Nitric oxide synthase is a multi-functional iso-enzyme and plays an important role in a series of tissues and organs (28) with the functional impairment of this enzyme, the amount of nitric oxide increased and could



affect the development of the embryo in several ways (29).

In biological conditions, there is always a physiological balance between the production and removal of free radicals of oxygen that interacting with this balance leads to cellular damages. BPA was also found to produce ROS and reduce antioxidant content in rats (30). On the other hand, using vitamin E in this study led to a significant reduction in the majority of fetal skeletal anomalies compared to the BPA group and this could be due to the effect of vitamin E antioxidant and the reduction of oxidative stress caused by using BPA. Other researchers, using different antioxidant effects of various compounds, reduced the fetal skeletal anomalies. Hebatalla et al. (2013) reduced skeletal anomalies due to BPA in rat fetuses using Omega-3 antioxidant effects (4).

Khaksary et al. (2016) emphasized the protective effects of quercetin as an antioxidant and pinpointed a reduction in the fetal skeletal anomalies induced by cyclophosphamide. However, a more accurate comment on this issue requires knowledge of the status of oxidative stress profile especially in fetuses (31). Using bromelain in this project could significantly reduce the skeletal anomalies due to BPA in fetal rats. In particular, bromelain with a dose of 40 mg/kg eliminated all skeletal anomalies, even better than vitamin E.

In vivo and in vitro studies have affirmed the anti-inflammatory properties of bromelain. It has also been shown in some empirical models that bromelain can inhibit oxidative stress (32). However, various studies have indicated the effect of bromelain immunization suggesting that it enhances the functioning of the immune system (17, 33).

On the other hand, the effect of stimulating the maternal immune system in preventing the teratogenic side effects caused by the administration of drugs and X-rays has been studied (34). Moreover, several reports have also noted the reduction of teratogenic effects, especially the cleft palate, by stimulating the maternal immune system (35, 36).

Considering the above-mentioned studies, it

can be noted that perhaps the beneficial effects of bromelain on reducing the skeletal anomalies of the fetal rats after administration of BPA in this study are also due to its immune function. Although it is not possible to discuss the protective mechanisms of bromelain to reduce skeletal anomalies, a comparison of the effect of bromelain with vitamin E, in this case, can be somewhat helpful. Since vitamin E is a well-known antioxidant, if bromelain functions only with antioxidant effects, it probably has the same results as vitamin E, while previous studies have been taking the protective properties of bromelain more than its antioxidant properties into account (15, 33). However, it should not be forgotten that both mechanisms may either have the same effect or reinforced each other to make this effect, like the study conducted by Prater et al. (2006) in which by intraperitoneal administration of an antioxidant, called butylated hydroxytoluene (BHT), to pregnant mice, the fetal skeletal anomalies were reduced by stimulating the immune system (37).

More precise comments on the protective mechanism of bromelain require supplementary studies, and issues such as oxidative stress profile, maternal and fetal safety indexes, and even inflammatory parameters should be compared in groups since bromelain also contains known anti-inflammatory effects (15) and on the other hand, BPA can also cause inflammation and necrosis of placenta cells (38).

### **Conclusion**

Regardless of the protective mechanism of bromelain, the results of the present study showed that this substance could well reduce skeletal anomalies caused by BPA (associated with the dose of administration) or even decline the defects to zero. However, further studies and clinical trials are needed. In this case, lower doses had fewer side effects, although a higher dose of bromelain further reduced skeletal anomalies.

### **Acknowledgments**

The authors would like to appreciate the Research Council of the Shahid Chamran University of Ahvaz for funding this study. Thesis



registration number: 90581172

### Conflict of interest

No conflict of interest is associated with this work.

The authors declare that this work was done by the authors named in this article and all liabilities about claims relating to the content of this article will be borne by them.

### References

1. Wang J, Schnute WC. Direct analysis of trace level bisphenol A, octylphenols and nonylphenol in bottled water and leached from bottles by ultra-high-performance liquid chromatography/tandem mass spectrometry. *Rapid Commun Mass Spectrom*. 2010; 24(17):2605-2610.
2. Hoekstra EJ, Simoneau C. Release of bisphenol A from polycarbonate—a review. *Crit Rev Food Sci Nutr*. 2013; 53(4):386-402.
3. Sharf-El Deen O, Bakry S, Shaeir WA, Mohammed FE, Adel M. Teratogenicity of Bisphenol-A (BPA) in Pregnant Rat. *Am-Eurasian J Toxicol Sci*. 2015; 7(4):229-238.
4. Hebatalla IA, EzzEldin E, Amany AA and Azza AA. The Possible Protective Effects of Some Antioxidants against Growth Retardation and Malformations Induced by Bisphenol-A in Rats. *Life Sci J*. 2013; 10(4): 1575-1586.
5. Snijder CA, Heederik D, Pierik FH, Hofman A, Jaddoe VW, Koch HM, et al. Fetal growth and prenatal exposure to bisphenol A: the generation R study. *Environ Health Perspect*. 2013; 121(3):393-398.
6. Hijazi A, Guan H, Cernea M, Yang K. Prenatal exposure to bisphenol A disrupts mouse fetal lung development. *FASEB J*. 2015; 29(12):4968-4977.
7. Nakagawa Y, Tayama S. Metabolism and cytotoxicity of bisphenol A and other bisphenols in isolated rat hepatocytes. *Arch Toxicol*. 2000; 74(2):99-105.
8. Jain S, Kumar CM, Suranagi UD, Mediratta PK. Protective effect of N-acetylcysteine on bisphenol A-induced cognitive dysfunction and oxidative stress in rats. *Food Chem Toxicol*. 2011; 49(6):1404-1409.
9. Berger RG, Hancock T, DeCatanzaro D. Influence of oral and subcutaneous bisphenol-A on intrauterine implantation of fertilized ova in inseminated female mice. *Reprod Toxicol*. 2007; 23(2):138-144.
10. Balci A, Ozkemahli G, Erkekoglu P, Zeybek ND, Yersal N, Kocer-Gumusel B. Histopathologic, apoptotic and autophagic, effects of prenatal bisphenol A and/or di (2-ethylhexyl) phthalate exposure on prepubertal rat testis. *Environ Sci Pollut Res*. 2020; 27(16): 20104-20116.
11. Huang W, Zheng S, Xiao J, Liu C, Du T, Wu K. Parental exposure to bisphenol A affects pharyngeal cartilage development and causes global transcriptomic changes in zebrafish (*Danio rerio*) offspring. *Chemosphere*. 2020; 249: 1-12.
12. Kabuto H, Amakawa M, Shishibori T. Exposure to bisphenol A during embryonic/fetal life and infancy increases oxidative injury and causes underdevelopment of the brain and testis in mice. *Life Sci*. 2004; 74(24): 2931-2940.
13. Napper AD, Bennett SP, Borowski M, Holdridge MB, Leonard MJ, Rogers EE, et al. Purification and characterization of multiple forms of the pineapple-stem-derived cysteine proteinases ananain and comosain. *Biochem J*. 1994; 301(3):727-735.
14. Irene D, Chen BJ, Lo SH, Liu TH, Tzen JT, Chyan CL. Resonance assignments and secondary structure of a phytocystatin from *Ananas comosus*. *Biomol NMR Assignments*. 2012; 6(1):99-101.
15. Rathnavelu V, Alitheen NB, Sohila S, Kanagesan S, Ramesh R. Potential role of bromelain in clinical and therapeutic applications. *Biomed Rep*. 2016; 5(3):283-288.
16. Duke JA, Bogenschutz-Godwin MJ, Ottesen AR. *Duke's Handbook of Medicinal Plants of Latin America*. 1st Edition. New York: CRC Press; 2008; 45.
17. Agarwal S, Chaudhary B, Renu B. Bacoside A and bromelain relieve dichlorvos induced changes in oxidative responses in mice serum. *Chem Biol Interact*. 2016; 254:173-178.
18. Sadeghi A, Farokhi F, Shalizer-Jalali A, Najafi G. Protective effect of vitamin E on sperm quality and in vitro fertilizing potential and testosterone concentration in polyvinyl chloride treated male rats. *Vet Res Forum*. 2020; 11(3):257-263.
19. Mustacich D, Powis G. Thioredoxin reductase. *Biochem J*. 2000; 346(1):1-8.
20. Rhee SG, Chae HZ, Kim K. Peroxiredoxins: a historical overview and speculative preview of novel mechanisms and emerging concepts in cell signaling. *Free Radic Biol Med*. 2005; 38(12):1543-52.
21. Mohd Mutalip SS, Ab-Rahim S, Rajikin MH. Vitamin E as an antioxidant in female reproductive health. *Antioxidants*. 2018; 7(2):1-15.
22. Khazaeel K, Jamshidian J, Khaksary-Mahabadi M, Zolfaghari N. Effect of Bromelain on Apparent Abnormalities Induced by Bisphenol A in Rat Fetus. *JIMS*. 2017; 35(452):1496-1503. [In Persian]
23. Aksoy N, Vural H, Sabuncu T, Arslan O, Aksoy S. Beneficial effects of vitamins C and E against oxidative stress in diabetic rats. *Nutr Res*. 2005; 25(6):625-630.
24. Guida M, Troisi J, Ciccone C, Granozio G, Cosimato C, Sardo AD, et al. Bisphenol A and congenital developmental defects in humans. *Mutat Res Fundam Mol Mech Mutagen*. 2015; 774:33-39.
25. Kim JC, Shin HC, Cha SW, Koh WS, Chung MK, Han SS. Evaluation of developmental toxicity in rats exposed to the environmental estrogen bisphenol A during pregnancy. *Life Sci J*. 2011; 69(22):2611-2625.
26. Couly G, Creuzet S, Bannaceur S, Vincent C, Le Douarin NM. Interactions between Hox-negative cephalic neural crest cells and the foregut endoderm in patterning the facial skeleton in the vertebrate head. *Development*. 2002; 129(4):1061-1073.





27. Li D, Fan H, Ye WJ, Hou HF. Developmental toxicity of Bisphenol-A on post implantation Rat Embryos Culture in Vitro. *Health Sci J*. 2010; 56(1):57-64.
28. Bloch W, Addicks K, Hescheler J, Fleischmann BK. Nitric oxide synthase expression and function in embryonic adult cardiomyocytes. *Microsc Res Tech*. 2001; (55):259-269.
29. Tsutsui M, Shimokawa H, Morishita T, Nakashina Y, Yanagihara N. Development of genetically engineered mice lacking all three nitric oxide synthases. *J Pharm Sci Exp Pharmacol*. 2006; 102:147-154.
30. Elswefy SE, Abdallah FR, Atteia HH, Wahba AS, Hasan RA. Inflammation, oxidative stress and apoptosis cascade implications in bisphenol A-induced liver fibrosis in male rats. *Int J Exp Pathol*. 2016; 97(5):369-379.
31. Khaksary Mahabady M, Gholami MR, Najafzade Varzi H, Zendedel A, Doostizade M. Protective effect of quercetin on skeletal and neural tube teratogenicity induced by cyclophosphamide in rat fetuses. *Vet Res Forum*. 2016; 7(2):133-138.
32. Lee JH, Lee JB, Lee JT, Park HR, Kim JB. Medicinal effects of bromelain (*Ananas comosus*) targeting oral environment as an anti-oxidant and anti-inflammatory agent. *J Food Nutr Res*. 2018; 6:773-784.
33. Engwerda CR, Andrew D, Ladhams A, Mynott TL. Bromelain modulates T cell and b cell immune responses in vitro and in vivo. *Cell Immunol*. 2001; 210(1): 66-75.
34. Holladay SD, Sharova LV, Punareewattana K, Hrubec TC, Gogal Jr RM, Prater MR, et al. Maternal immune stimulation in mice decreases fetal malformations caused by teratogens. *Int Immunopharmacol*. 2002; 2(2-3):325-332.
35. Holladay SD, Sharova LV, Smith BJ, Gogal RM, Ward DL, Blaylock BL. Nonspecific stimulation of the maternal immune system. I. Effect on teratogen-induced fetal malformation. *Teratol*. 2000; 62:413-419.
36. Rashidi F, Khaksary Mahabady M, Ranjbar R, and Najafzadeh H. The effects of Essential Oil of Galbanum on Caffeine Induced -Cleft palate in rat embryos. *Zahedan Int Res Med Sci*. 2014; 16(2):37-41.
37. Prater MR, Zimmerman KL, Pinn LC, Keay JM, Laudermlch CL, Holladay SD. Role of maternal dietary antioxidant supplementation in murine placental and fetal limb development. *Placenta*. 2006; 27(4-5):502-509.
38. Leclerc F, Dubois MF, Aris A. Maternal, placental and fetal exposure to bisphenol A in women with and without preeclampsia. *Hypertens Pregnancy*. 2014; 33(3):341-348.