



Case Report

Early Diagnosis of Schizophrenia and Secondary Diagnose of Cerebral autosomal Dominant Arteriopathy with Subcortical Infarcts and Leukoencephalopathy: A Case Report

Modaresi Farzaneh¹, Eslamzadeh Mahboubeh², Karimi Aliasghar^{3,4}, Ansari Amir^{5*}

1. Department of Psychiatry, Fasa University of Medical Sciences, Fasa, Iran

2. Psychiatry and Behavioral Sciences Research Center, Mashhad University of Medical Sciences, Mashhad, Iran

3. Noncommunicable Diseases Research Center, Fasa University of Medical Sciences, Fasa, Iran

4. Research Center for Neuromodulation and Pain, Shiraz University of Medical Sciences, Shiraz, Iran

5. Department of Internal Medicine, Fasa University of Medical Sciences, Fasa, Iran

Received: 14 May 2022 Accepted: 07 Jul 2022

Abstract

Background & Objective: Cerebral Autosomal Dominant Arteriopathy with Subcortical Infarcts and Leukoencephalopathy (CADASIL) is a rare disease with a prevalence estimation of, 5 per, 100,000 individuals. Besides, it can highly be misdiagnosed with other psychiatric disorders.

Case Presentation: We report a case of CADASIL in a 32-year-old Asian female presenting with schizophrenia symptoms such as auditory hallucination, loosening of associations, persecutory delusions, referential delusions, decreased function, and complex hepatic hallucinations that the patient had said sometimes someone has intercourse with me since 2 years ago. After brain Magnetic Resonance Imaging (MRI) and gene checking, she showed up with NOTCH3 gene, besides Brain Magnetic resonance imaging confirmed the presence of CADASIL. Supportive treatments have been done and two years of following up showed a significant increase in patient life quality.

Conclusion: This case report demonstrates the challenges of CADASIL diagnosis in a patient with schizophrenia symptoms. The diagnosis should be considered in patients with schizophrenia symptoms. Hence, there is a need for timely diagnosis and management of this disorder.

Keywords: CADASIL, Brain Magnetic resonance imaging, NOTCH3 Gene, schizophrenia

Introduction

Cerebral autosomal dominant arteriopathy with subcortical infarcts and leukoencephalopathy (CADASIL) is a rare disease with a prevalence estimation of, 5 per, 100,000 individuals and is caused by mutations in the NOTCH3 gene (1, 2).

***Corresponding Author:** Ansari Amir, Department of Internal Medicine, Fasa University of Medical Sciences, Fasa, Iran

Email: dr.amiransari84@yahoo.com

<https://orcid.org/0000-0002-2540-7910>

It can be determined by typical clinical manifestations including migraine with aura, progressive stroke, mood disorders, and cognitive impairment appearing in middle age (3). Loss of vascular smooth muscle cells and fibrosis of small penetrating vessels in patients results in chronic white matter ischemia that can cause dementia and disability (4). There are several methods to diagnose CADASIL:

Notch 3 testing is the first step of diagnosing, which helps in the detection of 90% of affected individuals (5), the manifestation of Brain Magnetic resonance imaging (MRI) in patients indicates cerebral white matter hyperintensity especially in capsule and temporal pole (6), another diagnosing approach is checking the presence of granular osmiophilic material (GOM) on skin biopsy. Also, recent studies show that checking the spatial distribution of lesions can be a useful approach to diagnosis (7).

It is worth mentioning that diagnosis approaches vary and misdiagnosis of CADASIL with other diseases like Multiple Sclerosis (MS) is possible, so, early diagnosis is a key to appropriate treatment (8, 9). Hence, reporting more cases advances our understanding of this disease and helps us for the right time management, which leads us to present a 32-year-old woman with schizophrenia clinical symptoms who was later diagnosed as a CADASIL case.

Case Presentation

Having obtained full informed consent, we describe a 32-year-old woman who was admitted to Shariati hospital as a Referral Tertiary Center affiliated with Fasa University of Medical Sciences, Fasa, Iran in January 2018. Her chief complaint was an auditory hallucination. Before her admission, no remarkable incidences such as strokes or past psychotic disorders had happened. On careful history taking, it emerged that she had no alcohol and smoking experience, on the other

hand, no background of chronic diseases such as blood pressure, diabetes, etc. has been reported by the patient. Neuraxial physical examination and routine blood and urine test at the begging of admission was done and all results were normal. The patient had symptoms of auditory hallucination such as “someone tells me to do some work” ‘loosening of associations’, persecutory delusions such as “other people want to kill me” ‘referential delusions such as “other people are talking about me” ‘decreased function and complex hepatic hallucinations that the patient had said sometimes someone has intercourse with me for the past two years which leads us to get suspicious to schizophrenia, according to the mentioned symptoms. This was our first diagnosis for the patient. However, by MRI and genetic test reports, the diagnosis has changed to CADASIL.

By more detailed history taking, we understood that the patient had no significant family history, not only about the background disease but also for having a CADASIL gene. First, the patient was submitted to MRI with the main complaint of dizziness and headache. There has been no history of trauma to the head and spine and the MRI report was as follows. The patient Subcortical and periventricular confluent WM T2 & FLAIR hypersignal intensities were seen. On the other hand, corpus collusion was involved too and we could see atrophic change involvement. In all lobes including temporal, parietal, occipital, and frontal, involvement was seen (Figure 1).

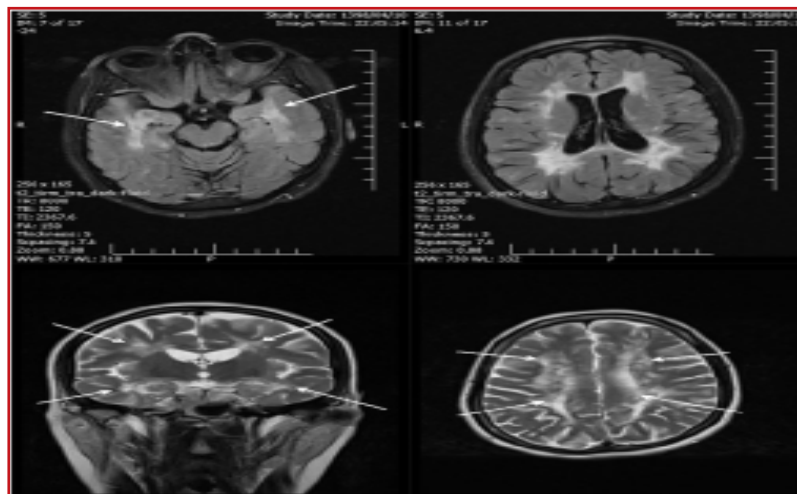


Figure 1. Widespread confluent supratentorial T2 and flair white matter hyperintensity is noted particularly in temporal lobes

The important point is that bilateral external capsule is not involved, but we cannot rule

out CADASIL because this condition can only be seen in 30 % of patients (Fig. 2).

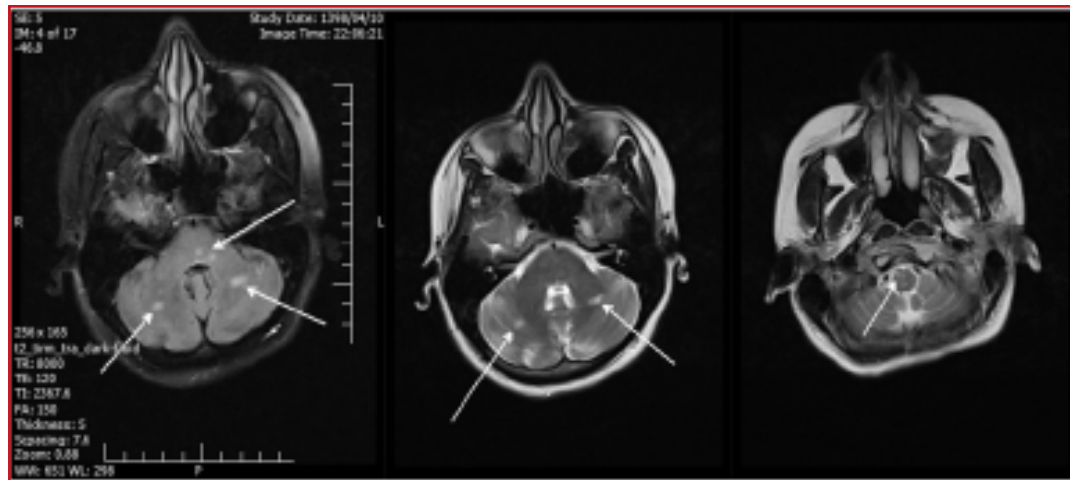


Figure 2. T2 and Flair hyperintense foci in brain stem and cerebellum

However, this MRI can be suggestive for CADASIL if the patient matches with it clinically. In addition, there are lesions in the cerebellum and brain (medulla and midbrain), which are beneficial for CADASIL. Therefore, it should be correlated with the patient's clinical condition. The absence of optic nerve and spinal cord involvement can lead to distinguishing multiple sclerosis (MS) from CADASIL. Adult-onset leukodystrophy was also considered, but more involvement of the white matter would be needed with this syndrome (10, 11). Vasculopathy such as small vessel cerebrovascular disease (SVCVD) cannot have a chance to be the last diagnosis due to lack of hypertension and the absence of anterior temporal lobe WM hyperintensity on T2-weighted MRI sequences (12). Therefore, at this age, other differential diagnoses such as vasculitis, which causes multiple infarcts in the field of coagulopathy, are not acceptable, so currently, the same diagnosis of CADASIL is relevant for the patient. Besides, we had no testing, financial, or cultural diagnostic challenges and genetic analysis was carried out based on the direct DNA sequencing of exons 3 and 4 of the Notch 3 gene. Therefore, CADASIL has been confirmed as the final diagnosis.

Discussion

This case report demonstrates the challenges of CADASIL diagnosis in a patient with schizophrenia symptoms. Although the prevalence of mood disorders, the presenting symptoms of CADASIL has been characterized, it is important to understand the similar symptoms and how they can be misdiagnosed (13).

CADASIL is the destruction of smooth vascular cells and impairment of vasoreactivity due to the accumulation of mutated NOTCH3 protein (14). The most trustable ways for diagnosing are screening exon 4, exons 3, 5, and 6. GOM on skin biopsy and anterior temporal pole involvement on MRI (7). Migraine with aura, transient ischemic attacks or stroke, psychiatric symptoms, and cognitive decline with vascular dementia are the major clinical symptoms of CADASIL. Besides, mood disorders and personality changes are the initial manifestations of CADASIL (15). For instance, the presentation of acute mania in a CADASIL patient as an initial alert has been reported, which is crucial to know how to deal with the situation (16). However, CADASIL patients presenting with schizophrenia symptom cases were almost rare. One case is a Chinese woman who was admitted



to the hospital. She had episodes of inappropriate laughing and crying and when she was talking, her speech was irrelevant with loosening of associations. Due to her psychotic symptoms and disorganized thoughts, she was diagnosed to have schizophreniform organic psychosis, which was an unusual first presentation in CADASIL (17). Schizophrenia is a severe and complex mental illness with a broad range of clinical and biological manifestations, which is among the world's top ten causes of long-term disability (18-20). The disease onset is in late adolescence or early adulthood, which can affect up to 1% of the population (With similar rates across different countries) (18, 21). Psychotic disorders, especially in early adulthood, are often diagnosed as schizophrenia (22). Accurate differential diagnoses of psychotic diseases for planning treatment and appropriate management are necessitated. In addition, misdiagnosing psychotic disorders such as schizophrenia and starting treatment may result in unnecessary use of antipsychotic drugs (22). For instance, a 67-year-old female patient was diagnosed with schizophrenia for fifteen years and later diagnosed as a CADASIL case (23). Also, in 2001, Pentti et al. reported a very rare case who was diagnosed with schizophrenia with the co-occurrence of CADASIL (24).

At present, there is no treatment for this disease, supportive and symptomatic treatments were done for the patient to decrease the further consequences. Thrombolytic therapy for stroke treatment in CADASIL patients is uncertain (25). Migraine should be treated symptomatically, which may include Acetazolamide and Sodium valproate usage. Our patient did not have hypertension and diabetes but if they existed, should have been treated (26). Psychological support and gene consulting is also needed (27). Aspirin 80 per day, Statin 20 per day, Antihypertensive therapy by losartan 25 per day, Antipsychotic by risperidone 1 mg at day and 1 mg at night, Glucose control by proper diet, psychological support and gene consulting was done for the patient. At the beginning of treatment with risperidone, she showed up with akathisia, which improved with the administration of propranolol.

Conclusion

After 3 years of following up, the patient's symptoms were mostly eased by symptomatic and supportive therapy and still were under control. The patient said that after taking drugs, her condition that someone intercourses with her was decreased. Hence, there is a need for timely diagnosis and management of this disorder. Further studies are needed to better apprehend the precise effects of cerebral tissue lesions and psychiatric symptoms in CADASIL patients.

Abbreviations

CADASIL: Cerebral Autosomal Dominant Arteriopathy with Subcortical Infarcts and Leukoencephalopathy, MRI: Magnetic resonance imaging, WM: White Matter, FLAIR: Coronal fluid-attenuated inversion recovery

Acknowledgments

We would like to thank the patient for her cooperation and Fasa University of Medical Sciences that financially supported this research. (Ethic Code: IR.FUMS.REC.1399.195, Grant Number: 99277)

Conflict of interests

The authors declare that there is no conflict of interest regarding the publication of this article.

References

1. Joshi S, Yau W, Kermode A. CADASIL mimicking multiple sclerosis: The importance of clinical and MRI red flags. *Journal of Clinical Neuroscience*. 2017;35:75-7.
2. Locatelli M, Padovani A, Pezzini A. Pathophysiological mechanisms and potential therapeutic targets in cerebral autosomal dominant Arteriopathy with subcortical infarcts and Leukoencephalopathy (CADASIL). *Frontiers in pharmacology*. 2020;11:321.
3. Chabriat H, Joutel A, Dichgans M, Tournier-Lasserre E, Bousser M-G. Cadasil. *The Lancet Neurology*. 2009;8(7):643-53.
4. Ruchoux M-M, Muraige C-A. CADASIL: cerebral autosomal dominant arteriopathy with subcortical infarcts and leukoencephalopathy. *Journal of Neuropathology & Experimental Neurology*. 1997;56(9):947-64.
5. Tournier-Lasserre E, Joutel A, Melki J, Weissenbach J, Lathrop GM, Chabriat H, et al. Cerebral autosomal dominant arteriopathy with subcortical infarcts and leukoencephalopathy maps to chromosome 19q12. *Nature genetics*. 1993;3(3):256-9.
6. Auer DP, Pütz B, Gössl C, Elbel G-K, Gasser T, Dichgans M. Differential lesion patterns in CADASIL and sporadic



- subcortical arteriosclerotic encephalopathy: MR imaging study with statistical parametric group comparison. *Radiology*. 2001;218(2):443-51.
7. Markus HS, Martin RJ, Simpson MA, Dong YB, Ali N, Crosby AH, et al. Diagnostic strategies in CADASIL. *Neurology*. 2002;59(8):1134-8.
 8. Motolese F, Rossi M, Gangemi E, Bersano A, Scelzo E, Di Lazzaro V, et al. CADASIL as Multiple Sclerosis Mimic: A 48-year-old man with severe leukoencephalopathy and spinal cord involvement. *Multiple sclerosis and related disorders*. 2020;41:102014.
 9. Zhu S, Nahas SJ. CADASIL: imaging characteristics and clinical correlation. *Current pain and headache reports*. 2016;20(10):1-5.
 10. Axelsen TM, Vammen TL, Bak M, Pourhadi N, Stenør CM, Grønberg S. Case report: 'AARS2 leukodystrophy'. *Molecular Genetics and Metabolism Reports*. 2021;28:100782.
 11. Suarez P, Restrepo L. Cerebrovascular disease, multiple sclerosis, or both? Case report and review of the challenging distinction between two potentially synergistic syndromes. *Cerebral Circulation - Cognition and Behavior*. 2021;2:100006.
 12. Monés J, Srivastava SK, Jaffe GJ, Tadayoni R, Albin TA, Kaiser PK, et al. Risk of inflammation, retinal vasculitis, and retinal occlusion-related events with brodalumab: post hoc review of HAWK and HARRIER. *Ophthalmology*. 2021;128(7):1050-9.
 13. Valenti R, Poggesi A, Pescini F, Inzitari D, Pantoni L. Psychiatric disturbances in CADASIL: a brief review. *Acta Neurol Scand*. 2008;118(5):291-5.
 14. Taieb G, Renard D, Castelnovo G. Simultaneous subcortical infarcts as initial manifestation of CADASIL. *Acta Neurologica Belgica*. 2015;115(3):385-6.
 15. Sangle N, Baringer JR, Majersik J, DeWitt LD. CADASIL with Multiorgan Involvement: a Complete Autopsy Examination Report. *Can J Neurol Sci*. 2016;43(1):202-5.
 16. Uppal M, Kanellopoulos D, Kotbi N. CADASIL presenting as late-onset mania with anosognosia. *Clinical case reports*. 2020;8(1):47-50.
 17. Joutel A, Vahedi K, Corpechot C, Troesch A, Chabriat H, Vayssiere C, et al. Strong clustering and stereotyped nature of Notch3 mutations in CADASIL patients. *Lancet*. 1997;350(9090):1511-5.
 18. Mueser KT, McGurk SR. Schizophrenia. *Lancet*. 2004;363(9426):2063-72.
 19. Stępnicki P, Kondej M, Kaczor AA. Current Concepts and Treatments of Schizophrenia. *Molecules*. 2018;23(8).
 20. Tomasik J, Rahmoune H, Guest PC, Bahn S. Neuroimmune biomarkers in schizophrenia. *Schizophr Res*. 2016;176(1):3-13.
 21. Charlson FJ, Ferrari AJ, Santomauro DF, Diminic S, Stockings E, Scott JG, et al. Global Epidemiology and Burden of Schizophrenia: Findings From the Global Burden of Disease Study 2016. *Schizophrenia Bulletin*. 2018;44(6):1195-203.
 22. Kokurcan A, Atbaşoğlu EC. [Differential Diagnosis of Schizophrenia: Psychotic Symptoms in Neurodevelopmental Disorders and Psychotic Disorders due to other Medical Conditions]. *Turk Psikiyatri Derg*. 2015;26(4):279-90.
 23. Göy D, Onur ÖŞ, Yesilkaya U. Schizophrenia likely related to be with cadasil: A case report. *European Psychiatry*. 2021;64(S1):S810-S.
 24. Pentti A. Schizophrenia in a patient with cerebral autosomally dominant arteriopathy with subcortical infarcts and leukoencephalopathy (CADASIL disease). *Nordic journal of psychiatry*. 2001;55(1):41-2.
 25. Tourtourikov I, Kadiyska T, Mitev V, Todorova A, Titianova E. Bulgarian mutations spectrum in Cadasil: Our experience. *Rad Hrvatske akademije znanosti i umjetnosti Medicinske znanosti*. 2021;547(54-55):10-9.
 26. Center TGAARDI. CADASIL 2018[Updated: Nov. 8, 2021] Available from: <https://rarediseases.info.nih.gov/diseases/1049/cadasil>.
 27. Information RD. CADASIL 2019[Updated 2019] Available from: <https://rarediseases.org/rare-diseases/cadasil/>.